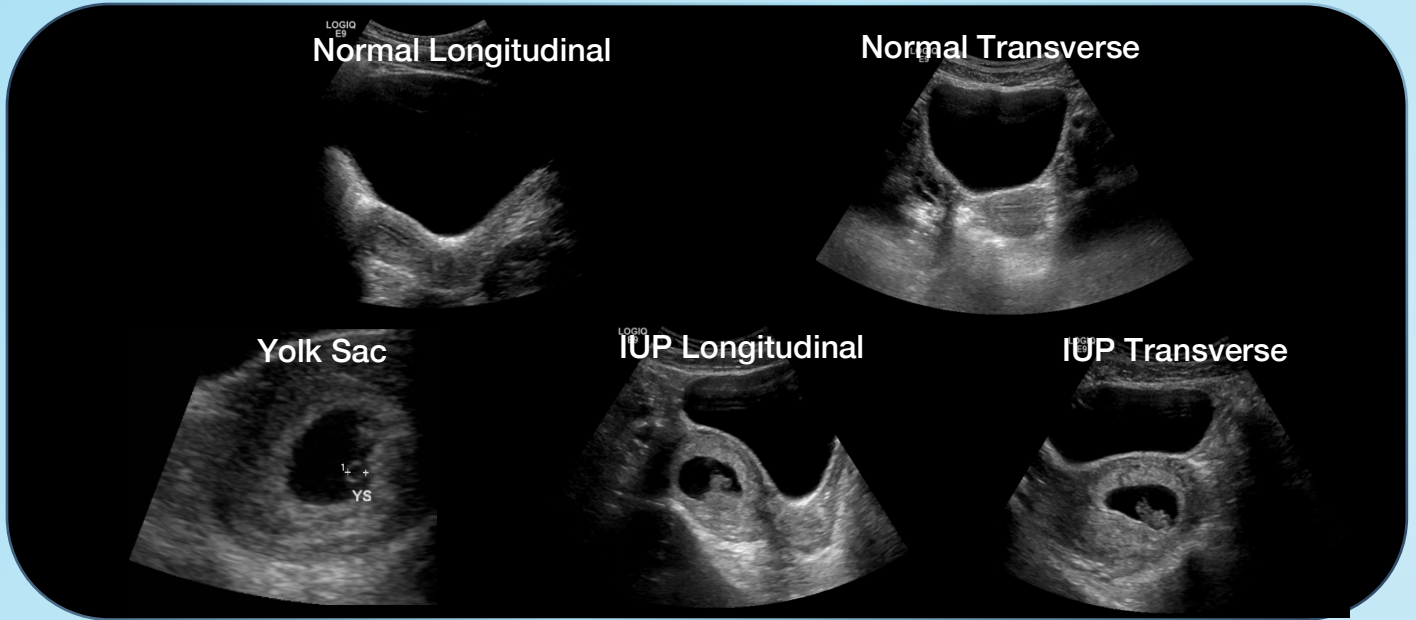
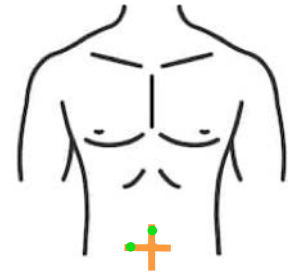




1st Trimester OB



Purpose: Identify intrauterine pregnancy (IUP)

Probe: Curvilinear (Abdo preset)

Orientation: Marker to patients right (transverse) and head (longitudinal)

Anatomic Landmarks: Pubic symphysis

Sono Landmarks: Bladder

Area of interest: Uterus (endometrial stripe)

Troubleshooting: Full bladder best. Use Zoom for fetal heart rate (FHR)

Confirming IUP:

1. Bladder-uterine juxtaposition
2. Gestational sac
3. Decidual reaction
4. Yolk sac (6-7wks) OR Fetal pole (7-8wks)
5. Myometrial mantle >1cm

Interpretations: If above criteria met, then ⁺IUP.
If not met then "No definitive IUP" (NDIUP)
↳ Proceed to scan RUQ for free fluid.
Expect FHR⁺ if pole > 7mm

False Positive: Hemorrhage mimicking yolk sac
Don't overcall FHR – activity must be w/in pole

Watch Out! Heterotopic pregnancy (IUP & EP) – more common with fertility treatment. In these patients, always get comprehensive ultrasound

Pitfalls : Pseudogestational sac of EP is not an IUP!
If >25mm consider anembryonic pregnancy ('blighted ovum')
If 'Swiss cheese' appearance consider molar pregnancy